



# Tuberous Sclerosis Complex and Cancer

Tunay DOĞAN,<sup>1</sup> Hülya YAZICI<sup>2</sup>

<sup>1</sup>Department of Medical Pathology, İstinye University Faculty of Medicine, İstanbul-Türkiye

<sup>2</sup>Department of Medical Biology and Genetics, İstanbul Arel University Faculty of Medicine, İstanbul-Türkiye

## SUMMARY

Tuberous sclerosis complex (TSC) is a neurocutaneous syndrome that can affect multiple organ systems such as the brain, heart, and lung, and neurological disorders such as autism spectrum disorder and mental retardation can be observed along with epileptic seizures in affected individuals. The disease can occur at any age. A genetic disease of TSC develops due to the mutations in *TSC1* and *TSC2* genes that cause dysfunction in Tuberin and/or Hamartin proteins. Although the disease has a highly variable penetrance, the cellular signal transduction mechanisms of TSC-related genes have largely been elucidated. The diagnostic criteria created by International TSC Consensus Group in 2012 are used in the diagnosis of the syndrome in addition to the genetic tests. At present, it is estimated that there are approximately 2 million people with TSC worldwide and 50,000 people are affected by the disease in the USA alone. It is important to know about the molecular genetics and clinical features of the disease for targeted therapies and well-managed surveillance. In the present study, we aimed to examine the genetic, biological, and clinical features of TSC and to discuss the genetic counseling approach that should be applied to patients with TSC.

**Keywords:** Cancer; genetic counseling; *TSC1*; *TSC2*; tuberous sclerosis complex.

Copyright © 2023, Turkish Society for Radiation Oncology

## INTRODUCTION

Tuberous sclerosis is a neurocutaneous disease; which was reported by Desire-Magloire Bourneville in 1880 when he named and reported the neuropathological findings as “tuberous sclerosis” detected in a young patient with mental abnormality, seizures, hemiplegia, and kidney tumors.[1] The involvement of the hamartomatous or benign lesions in brain, heart, lungs, and kidneys is generally detected in the presence of the disease. In addition, tuberous sclerosis epileptic seizures and neuropsychiatric disorders such as autism spectrum disorder (ASD) and mental retardation are commonly encountered. The disease is often named as tuberous sclerosis

complex (TSC) as the disease simultaneously affects various organ systems.[2] The *TSC1* and *TSC2* genes are responsible for TSC pathology, and the penetrance of these genes varies widely from patient to patient. Although it is known that there are approximately 2 million people with TSC worldwide and 50,000 people are affected by this disease in the USA alone, currently the incidence of the disease is approximately 1 in every 6,000–10,000 live births; and the prevalence is estimated as 1 in 20,000. The disease can occur in all races and ethnic groups and there is no difference between the sexes.[3,4] In terms of clinical features, individuals with TSC can vary widely, even within the same family. In the diagnosis, the diagnostic criteria created by the

Received: March 11, 2023

Accepted: March 27, 2023

Online: May 04, 2023

Accessible online at:

[www.onkder.org](http://www.onkder.org)

Dr. Hülya YAZICI

İstanbul Arel Üniversitesi Tıp Fakültesi,

Tıbbi Biyoloji ve Genetik Anabilim Dalı,

İstanbul-Türkiye

E-mail: [hulyayazici@arel.edu.tr](mailto:hulyayazici@arel.edu.tr)



International TSC Consensus Group in 2012 are used in addition to the genetic tests.[5] Treatment options are organized in accordance with the affected organ(s), and after diagnosis, the patients are followed up for symptoms at frequent intervals throughout their lives. Although inhibitors targeting TSC-related cell signaling pathway as a treatment option are very new, the number of studies on the efficacy of the epidemiological studies is scarce. In the present review, we have discussed the association of TSC with cancer in addition to its genetic, biological, and clinical features.

## THE GENETICS OF THE TSC

The genes associated with TSC disease were discovered as a result of multicentered, and genetic linkage analysis studies conducted with the inclusion of families with large number of TSC disease toward the end of the 1900s. Approximately 10 years after the first linkage analysis study, the *TSC1* gene encoding the 8.6 kb transcript, consisting of 23 exons and localized in the 55 kb area of 9q34.3; and in later studies, the *TSC2* gene, which is localized in the 40 kb area of 16p13.3, consists of 41 exons and encodes a 5.5 kb transcript, were found responsible for the disease.[6,7] At present, it is known that approximately 2/3 of individuals with TSC have de novo advanced germline mutations in *TSC1* or *TSC2* tumor suppressor genes; and 1 in 3 patients has hereditary *TSC1* or *TSC2* mutations and TSC shows an autosomal dominant inheritance pattern.[6] While there may be a mutation in only one of the genes responsible for the disease in patients with TSC, the detection of the mutations in both genes is quite rare; however, there are cases where mutations are detected in both genes. At present, 1135 unique variants for *TSC1* and 3261 unique variants for *TSC2* have been reported in the Leiden Open Variation database as of July 2020.[8] Mutations in *TSC1* are usually in the form of small insertion and deletion (indel) mutations that produce a premature stop codon leading to shortening of the protein (truncated gene product). However, large deletions, duplications, insertions and stop codon mutations (nonsense) and missense mutations are encountered in the *TSC2* gene.[7,9] These mutations are found to have spread through the encoding regions of the genes except for the exon 23 of *TSC1* and alternative spliced exons 25 and 31 of *TSC2*. TSC cases associated with *TSC1* gene mutations show a better phenotype than the phenotypes of the cases associated with *TSC2* gene mutations. It is also reported that *TSC1* is more commonly associated with familial TSC. In addition, some studies showed that there are differ-

ences in the severity of the disease phenotype, especially in terms of neuropsychiatric findings, related to the localization of mutations in *TSC1* and *TSC2* mutations.[4]

The small mutational changes commonly detected in *TSC1* and *TSC2* genes[6] are given in Tables 1 and 2. *TSC2* mutations have been shown to be present in approximately 70%, and *TSC1* gene mutations in 20% of TSC patients. Although TSC findings were detected in the remaining 10% of individuals, mutations in *TSC1* and *TSC2* genes have not been reported, and there may be other genes responsible for TSC in individuals in this group.[4,9] It was suggested that the possible genes might be the other genes that play a role in the signaling pathway where the *TSC1* and *TSC2* were associated with, however, no evidence was found to support this idea in the studies.[9] In the studies using the next-generation sequencing (NGS) technologies and RNA-based approaches, it was observed that TSC patients who were suggested to have no mutations in *TSC1* and *TSC2* genes actually carried low-level somatic mosaicism and intronic splicing variants affecting *TSC1* and *TSC2* genes.[10,11] After this information, researchers reached to a consensus that there is no third gene which is directly responsible for the development of TSC. As an exception, although not directly responsible for the development of TSC, the Polycystin 1 (*PKD1*) gene is adjacent to *TSC2* on chromosome 16, and polycystic kidney disease (PKD) was reported to have been detected as a different phenotype in TSC when the large deletions detected in *TSC2* also affect *PKD1*. [12]

Knudson's "two hit" hypothesis is of great importance in understanding the variable clinical manifestations as well as development of lesion in TSC syndrome. Individuals with TSC who are born with defect in one of the alleles of the tumor suppressor *TSC1* or *TSC2* genes sporadically or with a germline, show TSC findings in their phenotype and develop tumors localized in different organs due to the biallelic inactivation when they lose the function of the non-defective copy of the *TSC1* or *TSC2* genes due to the second hit mutation to develop later.[13,14] Figure 1 summarizes the localization of *TSC1* and *TSC2* genes on the relevant chromosomes, the physical features of the genes and the development of Loss of Heterozygosity (LOH) with the two hit hypothesis.

## THE CELL SIGNAL PATHWAY IN TSC

The *TSC1* gene encodes the 130 kDa Hamartin protein consisting of 1164 amino acids, and the *TSC2* gene encodes the 198 kDa Tuberin protein consisting of 1807

**Table 1** The commonly encountered mutations in *TSC1* gene of TSC patients, and their characteristics (was taken and adapted from reference 6)

Gene	Exon	Mutation	Amino acid change	Mutation type
<i>TSC1</i>	15	c.1888_1891del	Lys630GlnfsX22	Deletion
<i>TSC1</i>	17	c.2074C > T	Arg692X	Nonsense*
<i>TSC1</i>	15	c.1525C > T	Arg509X	Nonsense
<i>TSC1</i>	8	c.733C > T	Arg245X	Nonsense
<i>TSC1</i>	18	c.2356C > T	Arg786X	Nonsense
<i>TSC1</i>	8	c.682C > T	Arg228X	Nonsense
<i>TSC1</i>	15	c.1903_1904del	Thr635ArgfsX52	Deletion
<i>TSC1</i>	10	c.989dupT	Ser331GlnfsX10	Insertion
<i>TSC1</i>	21	c.2672dupA	Asn891LysfsX13	Insertion

\*: Nonsense: Stop codon mutation. TSC: Tuberous Sclerosis Complex

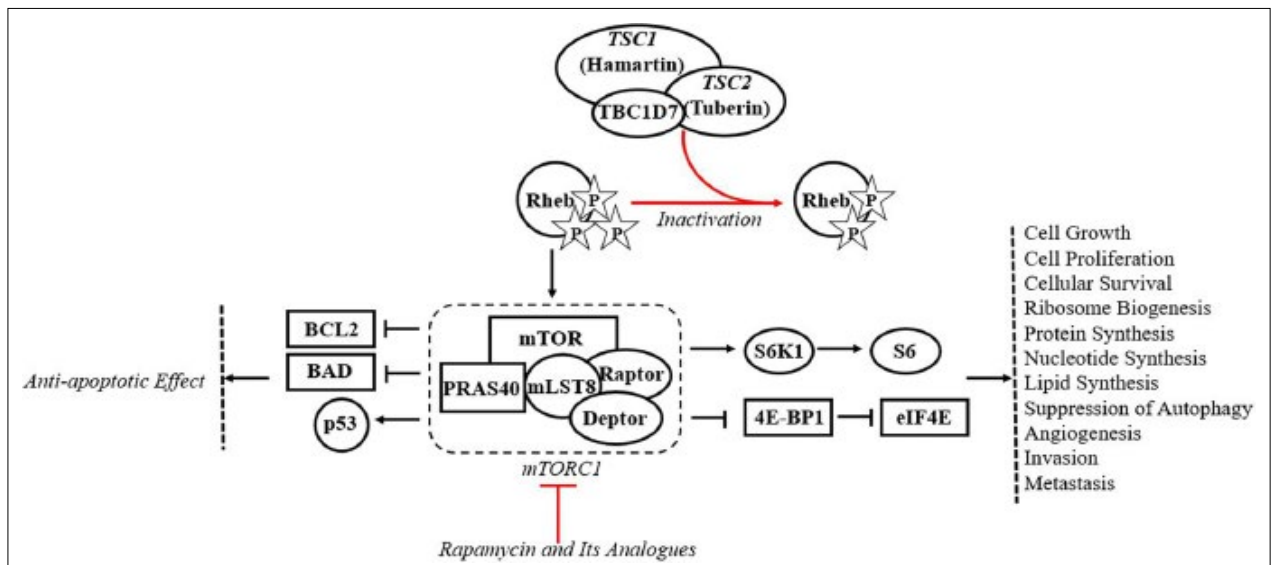
**Table 2** The commonly encountered mutations in *TSC2* gene of TSC patients, and their characteristics (was taken and adapted from reference 6)

Gene	Exon	Mutation	Amino acid change	Mutation type
<i>TSC2</i>	40	5238_5255del18	His1746_Arg1751 delinsGln	18nt In-frame deletion
<i>TSC2</i>	16	1832G > A	Arg611Gln	Missense*
<i>TSC2</i>	38	5024C > T	Pro1675Leu	Missense
<i>TSC2</i>	23	2713C > T	Arg905Trp	Missense
<i>TSC2</i>	16	1831C > T	Arg611Trp	Missense
<i>TSC2</i>	40	5227C > T	Arg1743Trp	Missense
<i>TSC2</i>	13	1372C > T	Arg458X	Nonsense**
<i>TSC2</i>	14	1513C > T	Arg505X	Nonsense
<i>TSC2</i>	29	3412C > T	Arg1138X	Nonsense
<i>TSC2</i>	33	4375C > T	Arg1459X	Nonsense
<i>TSC2</i>	30	3693_3696del	Ser1232ThrfsX92	4nt Deletion

\*: Missense: Mismatch; \*\*: Nonsense: Stop codon mutation. TSC: Tuberous Sclerosis Complex

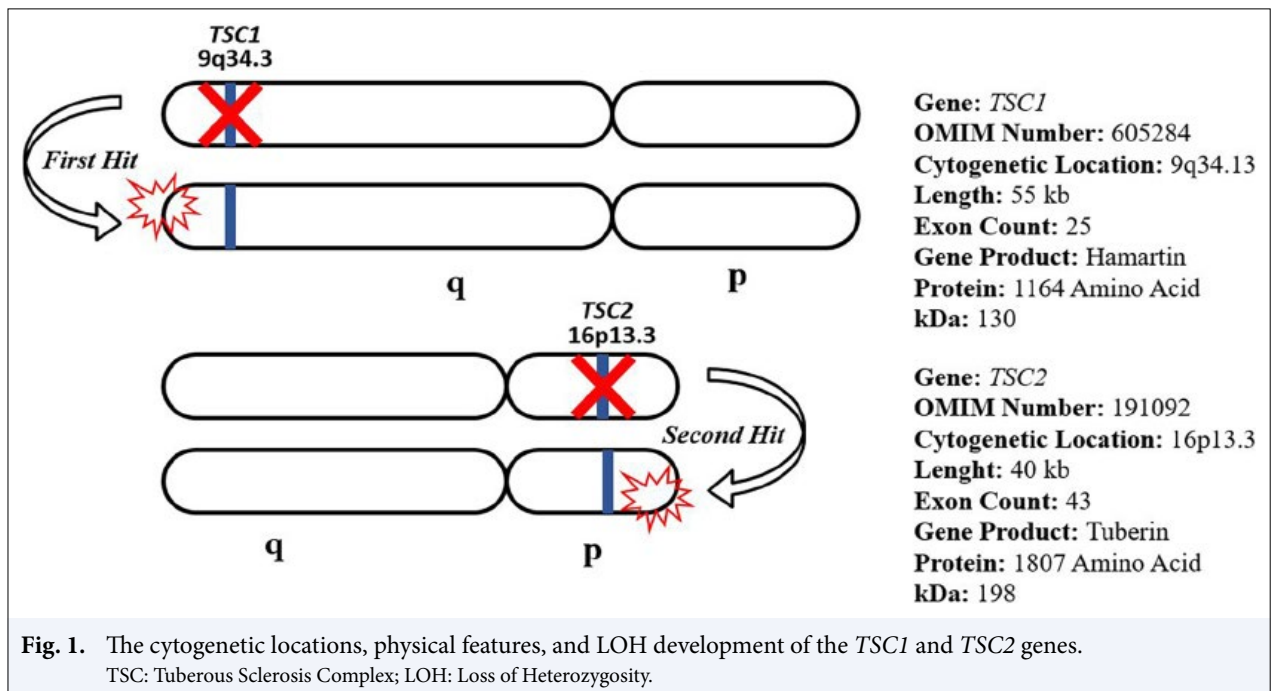
amino acids. The complex formed by these two tumor suppressor proteins are known to play a suppressive role in the regulation of the mammalian/mechanistic target of rapamycin (mTOR) signaling pathway. [15] Hamartin and Tuberin proteins form a heterotrimeric protein complex with TBC1 domain family member 7 in the cell. This heterotrimeric complex dephosphorylates Rheb (RAS Homologous Enriched in Brain) through its GTPase activating domain and inactivates Tuberin. Rheb is in active form when it is bound to GTP. The active Rheb mTOR activates the mTORC1 complex consisting of mLST8 (Mammalian Lethal with SEC13 Protein 8), PRAS40 (Proline-Rich Akt Substrate, 40 kDa), Raptor and Deptor.[16,17] The activated mTORC1 complex becomes the driving force for the cellular events such as cell growth, ribosome biogenesis, protein synthesis, nucleotide synthesis, lipid synthesis, proliferation, cellular sur-

vival, invasion, and metastasis through activation of S6K (Ribosomal Protein S6 Kinase 1) and suppression of 4E-BP1 (Eukaryotic Translation Initiator Protein 4E-Linking Protein 1). In response to all these events, while the activated mTORC1 complex suppresses autophagy, on the other hand, it may show to have an anti-apoptotic effect by suppressing Bcl-2 and Bad, by increasing the p53 activation.[18–21] In TSC patients, an active heterotrimeric protein complex cannot be formed due to the inability to express Hamartin or Tuberin proteins as a result of mutations in the *TSC1* or *TSC2* tumor suppressor genes or due to the formation of a shortened gene product. Therefore, the Rheb and indirectly the mTORC1 protein complex remain constantly activated. This mechanism is suggested to be underlying in the formation of hamartomatous lesions in patients with TSC. Currently, Rapamycin and its analogs are known as the inhibitors of mTORC1.



**Fig. 2.** The association of mTOR pathway with the Hamartin and Tuberin proteins.

TSC: Tuberous Sclerosis Complex; TBC1D7: TBC1 Domain Family Member 7; Rheb: RAS Homologous Enriched in Brain; BCL2: B-cell Lymphoma 2 (Apoptosis Regulator); BAD: BCL2 Associated Agonist of Cell Death; mTOR: Mechanistic target of rapamycin; PRAS40: Proline-Rich Akt Substrate, 40 kDa; mLST8: Mammalian Lethal with SEC13 Protein 8; mTORC1: Mammalian Target of Rapamycin Complex 1; S6K1: Ribosomal Protein S6 Kinase Beta-1; 4E-BP1: Eukaryotic Translation Initiation Factor 4E-Binding Protein 1; eIF4E: Eukaryotic Translation Initiation actor 4E.



**Fig. 1.** The cytogenetic locations, physical features, and LOH development of the *TSC1* and *TSC2* genes.

TSC: Tuberous Sclerosis Complex; LOH: Loss of Heterozygosity.

Rapamycin is used as a treatment option in many other diseases, particularly in TSC.[22,23] In the light of this information, the relationship between the mTOR pathway and the Hamartin and Tuberin proteins is summarized in Figure 2 in details.

## THE DIAGNOSTIC CRITERIA IN TSC

The diagnosis in TSC is made according to the diagnostic criteria determined by the International TSC Consensus Group in 2012. The diagnostic criteria are

**Table 3** The clinical diagnosis criteria updated in 2012 by the International Tuberous Sclerosis Complex Consensus Group

Major criteria	Minor criteria
1 Hypomelanotic macules ( $\geq 3$ , $\geq 5$ mm diameter)	1 Confetti skin lesions
2 Angiofibromas ( $\geq 3$ in number) or fibrous cephalic plaque	2 Dental enamel pits ( $\geq 3$ in number)
3 Ungual fibromas ( $\geq 2$ in number)	3 Intraoral fibromas ( $\geq 2$ in number)
4 Shagreen patch	4 Retinal achromic patch
5 Multiple retinal hamartomas	5 Multiple renal cysts
6 Cortical dysplasia	6 Extrarenal hamartomas
7 Subependymal nodule	
8 Subependymal giant cell astrocytoma	
9 Cardiac rhabdomyoma	
10 Lymphangiomyomatosis (LAM)	
11 Angiomyolipomas (AML) ( $\geq 2$ in number)	

divided into two as genetic diagnostic criteria, and clinical diagnostic criteria. The genetic diagnostic criteria include the demonstration of a pathogenic mutation in one of the *TSC1* or *TSC2* genes with a genetic test to be made from a normal tissue and can provide a definitive diagnosis. The pathogenic mutation described here is the changes which inactivate the function of Hamartin or Tuberin proteins to be produced from the *TSC1* or *TSC2* genes, or the changes that prevent protein synthesis.[5,24] As stated under the heading “genetics of TSC,” approximately 90% of individuals with TSC have a mutation in either *TSC1* or *TSC2* genes. However, in the remaining 10%, mutations may not be detected in the regions targeted by conventional genetic tests. In this context, the fact that genetic testing showing no presence of mutation or that the patient has one of the non-pathogenic mutation variants[8] does not exclude TSC. When the presence of mutations in *TSC1* or *TSC2* genes is demonstrated in a patient with TSC, genetic testing has high predictive value for other family members as well. However, it should be kept in mind that clinical features can show wide variation even among family members with TSC who have the same mutation. In addition, it should be taken into account that in most countries individuals will not have the opportunity to access genetic testing. Therefore, the genetic diagnostic criteria and clinical diagnostic criteria should be considered and evaluated separately for a definitive diagnosis. The clinical diagnostic criteria consist of a set of major and minor criteria as shown in Table 3. For the “definitive” diagnosis of TSC, 2 major criteria, or 1 major criterion and 2 minor criteria must be met simultaneously. Individuals with only one major criterion, or with only 2 or more of the minor criteria at the same time, are reported as “potential” TSC patients.[5]

### THE CLINICAL FEATURES OF THE TSC

TSC affects many organs at the same time and with different severity and shows high clinical heterogeneity. The most characteristic findings in TSC are the cutaneous lesions, occurring in approximately 90% of cases.[25] Different dermatological symptoms can be encountered at each stage from birth to adulthood. The most common lesions of ash-leaf spots, are the hypomelanotic macules that can be visualized with a wood lamp from infancy.[25,26] Angiofibromas, also called adenoma sebaceum, constitute the second most common lesion after an average of 9 years of age. Other dermatological findings characterized by TSC include the fibrous cephalic plaques on the forehead, shagreen spots on the back, confetti skin lesions, ungual and gingival fibromas, and dental enamel pits.[27,28] Renal angiomyolipoma (AML) involvement is detected in 80% of TSC patients, and kidney disorders have the largest share in terms of TSC-related morbidity. Rare cases of renal cell carcinoma have also been reported. PKD is observed when *TSC2*-related mutations affect the *PKD1* gene.[29] Epileptic seizures, the most prominent feature of neurological involvement, together with dermatological findings, constitute the primary reason for presenting to the clinic of TSC patients. Although epileptic seizures are commonly seen in the first 3 years of life, they can occur at any age. In addition to epilepsy, ASD, mental retardation, behavioral disorders, attention deficit, and hyperactivity are among the TSC-associated neuropsychiatric disorders (TAND).[30,31] The other neurological problems can be listed as subependymal nodules causing structural disorders in the brain, subependymal giant cell astrocytomas (SEGA), cortical dysplasia, and cortical tubers.[32,33] Although cardiac rhabdomyomas in the form

of abnormal myocyte collections are observed in prenatal ultrasound performed between the 20<sup>th</sup> and 30<sup>th</sup> weeks of gestation in at least half of the individuals with TSC, the lesions are reported to have usually regressed spontaneously after the first 3 years of age.[34] Although lymphangiomyomatosis (LAM), which progresses with cough, hemoptysis, pneumothorax, and shortness of breath, is a pulmonary disorder affecting 40% of individuals with TSC, it almost always occurs in adult women and is rarely encountered in symptomatic men.[35] The most important ophthalmologic involvement in TSC is the retinal astrocytic hamartomas, which is detected in almost half of the patients. These lesions rarely cause visual impairment. Less frequently, some other abnormalities may be encountered in the retina, such as hypopigmented macules, palpebral angiofibromas, colobomas, and iris depigmentation.[36] In the light of this information, it can be suggested that the organs mostly affected by TSC are the skin, brain, kidney, heart, lung, and eye; however, abnormal tubers and cysts can be encountered in other parts of the body due to uncontrolled cell division and proliferation associated with loss of function in *TSC1* and *TSC2* tumor suppressor genes.[4,37] Hamartomas and polyps in the gastrointestinal tract, detected especially in the stomach, intestines and/or colon, are usually small and rarely cause symptoms; rectal polyps may be seen in some cases.[4,38,39] Sclerotic and hypertrophic lesions in the bones, benign liver tumors that are 5 times more common in women, pancreatic neuroendocrine tumors in some cases, and large and progressive hamartomas may be present in the spleen in some patients.[4,37,39,40]

## THE FOLLOW-UP AND TREATMENT IN TSC

TSC is a chronic and rare genetic disease. The vast majority of cases have a near-normal life expectancy, however, the high morbidity and TSC-associated mortality rates, which vary depending on symptoms, are also at a substantial level.[41,42] This requires individuals with TSC to be followed-up clinically with a multidisciplinary approach specific to TSC at frequent intervals after diagnosis and needs the continuity of surveillance. The optimal treatment for new symptoms emerging during the follow-up period should be decided with the patient and caregivers. The mTOR pathway inhibition by rapamycin and its analogues (sirolimus and everolimus approved for TSC) is a great source of hope for patients, however its long-term effects are not well understood since its clinical use began in 2003.[15,43] The other treatment options vary according to the affected organ. In the fol-

low-up process of TSC patients, the most comprehensive examination is neurological examination. The patients are recommended to have MRI in every 1–3 years for the development of SEGA until the age of 25 years. In the case of SEGA, the classical treatment is surgical resection, although mTOR pathway inhibition with everolimus is considered successful.[44] The need of EEG for epileptic seizures varies according to clinical need; and the use of steroids, anticonvulsants, clobazam and vigabatrin, vagal nerve stimulation, ketogenic diet, and surgical resection options are evaluated for the treatment of epilepsy and infantile spasms.[45,46] Another group of TSC findings that require periodic screening is TAND, and special education programs, neuropsychiatric evaluation and rehabilitation are of great importance.[47,48] The screening approach for signs of LAM includes high-resolution CT imaging every 2–3 years, as well as annual repeat pulmonary tests such as pulmonary function tests, diffusion capacity measurement, and oxygen monitoring during exercise.[49,50] For signs of LAM, inhibition of the mTOR pathway with sirolimus demonstrates successful results.[49,50] Annual clinical examination is recommended for skin, eye and oral lesions, and it is critical to monitor the shape changes in the lesions. Patients should be protected from sunlight. Treatment options for dermatological lesions include carbon dioxide laser ablation and surgical resection, as well as topical application of rapamycin for mTOR pathway inhibition.[26,51] The follow-up of kidney functions and the development of AML is also an important issue in the TSC. It is recommended to perform renal function tests such as annual blood pressure measurement and annual glomerular filtration rate measurement, as well as abdominal MRI and CT imaging every 1–3 years after TSC diagnosis.[29,52] Nephron-sparing surgical resection and percutaneous embolization are among the treatment options, however surgery is avoided as much as possible. Inhibition of the mTOR pathway by everolimus has been found successful in the treatment of AML.[52,53] Cardiological follow-up is generally important in the presence of rhabdomyoma in TSC. Since cardiac rhabdomyomas may regress spontaneously after childhood, echocardiogram every 1–3 years and an ECG every 3–5 years are recommended until recovery is observed.[54] Although some studies emphasized the contribution of the use of everolimus and sirolimus with mTOR pathway inhibition to cardiac rhabdomyoma regression, there are uncertainties in the clinical use.[55,56] Apart from these, the follow-up and treatment options for less common organ involvements vary according to the clinical features of the cases.

## GENETIC COUNSELING IN TSC

TSC is an autosomally dominant inherited disease, and the affected individual has a 50% chance of transmitting the pathogenic variant of the *TSC1* and *TSC2* genes to their offspring. Detection of the pathogenic variant as a result of genetic testing in an affected family member provides the genetic counselor with the opportunity to predict the disease for other family members. If a high-risk pathogenic variant is detected in the TSC patient, they must be informed on the risks of pregnancy, prenatal tests and pre-implantation genetic diagnosis. Apart from this, the family tree should be drawn including at least three generations of the patient, and other affected individuals and their symptoms should be recorded in the family tree in details. Even among family members carrying the same mutation in TSC, the reflection of the symptoms related to the disease to the phenotype can show wide variation. Therefore, family trees can show the affected, asymptomatic and high-risk individuals at the same time and with a holistic view and can give an idea to the consultant about the penetrance of the disease. Apart from these, if possible, a copy of the previous clinical tests and imaging reports, especially the pathology reports, should be requested from the people who will be given genetic counseling and added to the patient's file. In the briefing by the consultant, the family tree, genetic test result and previous clinical reports of the patient should be evaluated together.

## CONCLUSION

TSC is a chronic and rare genetic disease. This neurocutaneous disease with an autosomal-dominant inheritance pattern is not only genetically heterogeneous, but also highly variable phenotypically and clinically. Investigation of genetic variations of *TSC1* and *TSC2* genes and other TSC-related genes responsible for the disease with powerful genetic tools such as NGS technologies in patients with suspected TSC is important in terms of elucidating cellular signaling mechanisms and developing therapeutic targets. The expansion of our current knowledge of the TSC-related intracellular signaling cascade has implications for the development of new therapeutic targets that can reverse the clinical phenotype of the disease. Diagnosis of patients in accordance with the diagnostic criteria established by the International TSC Consensus Group, lifelong follow-up of patients and appropriate genetic counseling will contribute to reducing the prevalence of TSC.

**Peer-review:** Externally peer-reviewed.

**Conflict of Interest:** The authors declare no conflicts of interest.

**Financial Support:** The authors received no financial support for the publication of this article.

## REFERENCES

- Gómez MR. History of the tuberous sclerosis complex. *Brain De.* 1995;17(Suppl):55–7.
- Roach ES, Sparagana SP. Diagnosis of tuberous sclerosis complex. *J Child Neurol* 2004;19(9):643–9.
- Angela V, Sala G, Lesma E, Labriola F, Riighetti M, Alfano RM, et al. Tuberous sclerosis complex: new insights into clinical and therapeutic approach. *J Nephrol* 2019;32:355–63.
- Henske EP, Józwiak S, Kingswood JC, Sampson JR, Thiele EA. Tuberous sclerosis complex. *Nat Rev Dis Primers* 2016;2:16035.
- Northrup H, Krueger DA; International Tuberous Sclerosis Complex Consensus Group. Tuberous sclerosis complex diagnostic criteria update: recommendations of the 2012 International Tuberous Sclerosis Complex Consensus Conference. *Pediatr Neurol* 2013;49(4):243–54.
- Kwiatkowski DJ, Whittemore VH, Thiele EA, editors. *Tuberous sclerosis complex: genes, clinical features and therapeutics.* New Jersey: John Wiley & Sons; 2011.
- Kozłowski P, Roberts P, Dabora S, Franz D, Bissler J, Northrup H, et al. Identification of 54 large deletions/duplications in *TSC1* and *TSC2* using MLPA, and genotype-phenotype correlations. *Hum Genet* 2007;121(3-4):389–400.
- LOVD development team, LUMC. All Genes - Global Variome Shared LOVD, 4 July 2020. Available at: [https://databases.lovd.nl/shared/genes?search\\_name=tuberous+sclerosis](https://databases.lovd.nl/shared/genes?search_name=tuberous+sclerosis). Accessed Apr 6, 2023.
- Caban C, Khan N, Hasbani DM, Crino PB. Genetics of tuberous sclerosis complex: implications for clinical practice. *Appl Clin Genet* 2016;10:1–8.
- Nellist M, Brouwer RW, Kockx CE, van Veghel-Plandsoen M, Withagen-Hermans C, Prins-Bakker L, et al. Targeted Next Generation Sequencing reveals previously unidentified *TSC1* and *TSC2* mutations. *BMC Med Genet* 2015;16:10.
- Tyburczy ME, Dies KA, Glass J, Camposano S, Chekaluk Y, Thorner AR, et al. Mosaic and intronic mutations in *TSC1/TSC2* explain the majority of TSC patients with no mutation identified by conventional testing. *PLoS Genet* 2015;11(11):e1005637.
- Pema M, Drusian L, Chiaravalli M, Castelli M, Yao Q, Ricciardi S, et al. mTORC1-mediated inhibition of polycystin-1 expression drives renal cyst forma-

- tion in tuberous sclerosis complex. *Nat Commun* 2016;7:10786.
13. Knudson AG Jr. Mutation and cancer: statistical study of retinoblastoma. *Proc Natl Acad Sci U S A* 1971;68(4):820–3.
  14. Idogawa M, Hida T, Tanaka T, Ohira N, Tange S, Sasaki Y, et al. Renal angiomyolipoma (AML) harboring a missense mutation of TSC2 with copy-neutral loss of heterozygosity (CN-LOH). *Cancer Biol Ther* 2020;21(4):315–9.
  15. Tee AR, Manning BD, Roux PP, Cantley LC, Blenis J. Tuberous sclerosis complex gene products, Tuberin and Hamartin, control mTOR signaling by acting as a GTPase-activating protein complex toward Rheb. *Curr Biol* 2003;13(15):1259–68.
  16. Orlova KA, Crino PB. The tuberous sclerosis complex. *Ann N Y Acad Sci* 2010;1184:87–105.
  17. Ken I, Corradetti MN, Guan KL. Dysregulation of the TSC-mTOR pathway in human disease. *Nat Genet* 2005;37:19–24.
  18. Saxton RA, Sabatini DM. mTOR Signaling in Growth, Metabolism, and Disease. *Cell* 2017;168(6):960–76.
  19. Jozwiak J, Jozwiak S, Grzela T, Lazarczyk M. Positive and negative regulation of TSC2 activity and its effects on downstream effectors of the mTOR pathway. *Neuromolecular Med* 2005;7(4):287–96.
  20. Yoshida S, Hong S, Suzuki T, Nada S, Mannan AM, Wang J, et al. Redox regulates mammalian target of rapamycin complex 1 (mTORC1) activity by modulating the TSC1/TSC2-Rheb GTPase pathway. *J Biol Chem* 2011;286(37):32651–60.
  21. DiMario Jr, Francis J. Tuberous sclerosis complex. In: *Harper's Textbook of Pediatric Dermatology*. New Jersey: Wiley; 2019. p. 1837–56.
  22. Ehninger D, Silva AJ. Rapamycin for treating Tuberous sclerosis and Autism spectrum disorders. *Trends Mol Med* 2011;17(2):78–87.
  23. Davies DM, de Vries PJ, Johnson SR, McCartney DL, Cox JA, Serra AL, et al. Sirolimus therapy for angiomyolipoma in tuberous sclerosis and sporadic lymphangioleiomyomatosis: a phase 2 trial. *Clin Cancer Res* 2011;17(12):4071–81.
  24. Hodges AK, Li S, Maynard J, Parry L, Braverman R, Cheadle JP, et al. Pathological mutations in TSC1 and TSC2 disrupt the interaction between hamartin and tuberin. *Hum Mol Genet* 2001;10(25):2899–905.
  25. Jindal R, Jain A, Gupta A, Shirazi N. Ash-leaf spots or naevus depigmentosus: a diagnostic challenge. *BMJ Case Rep* 2013;2013:bcr2012007008.
  26. Fakhari DE, Meyer S, Vogt T, Pföhler C, Müller CSL. Dermatological manifestations of tuberous sclerosis complex (TSC). *JDDG* 2017;15(7):695–700.
  27. Nguyen QD, DarConte MD, Hebert AA. The cutaneous manifestations of tuberous sclerosis complex. *Am J Med Genet C Semin Med Genet* 2018;178(3):321–5.
  28. Pithadia DJ, Treichel AM, Jones AM, Julien-Williams P, Machado T, Moss J, et al. Dermatological adverse events associated with use of oral mechanistic target of rapamycin inhibitors in a cohort of individuals with tuberous sclerosis complex. *Br J Dermatol* 2020;183(3):588–9.
  29. Kingswood JC, Bissler JJ, Budde K, Hulbert J, Guay-Woodford L, Sampson JR, et al. Review of the tuberous sclerosis renal guidelines from the 2012 consensus conference: current data and future study. *Nephron* 2016;134(2):51–8.
  30. de Vries PJ, Belousova E, Benedik MP, Carter T, Cottin V, Curatolo P, et al; TOSCA Consortium and TOSCA Investigators. TSC-associated neuropsychiatric disorders (TAND): findings from the TOSCA natural history study. *Orphanet J Rare Dis* 2018;13(1):157.
  31. Loren L, de Vries P. Towards an improved understanding of TSC-associated neuropsychiatric disorders (TAND). *Advances in Autism* 2016;2(2):76–83.
  32. Józwiak S, Nabbout R, Curatolo P; participants of the TSC Consensus Meeting for SEGA and Epilepsy Management. Management of subependymal giant cell astrocytoma (SEGA) associated with tuberous sclerosis complex (TSC): Clinical recommendations. *Eur J Paediatr Neurol* 2013;17(4):348–52.
  33. Curatolo P, Verdecchia M, Bombardieri R. Tuberous sclerosis complex: a review of neurological aspects. *Eur J Paediatr Neurol* 2002;6(1):15–23.
  34. Kocabaş A, Ekici F, Cetin İİ, Emir S, Demir HA, Arı ME, et al. Cardiac rhabdomyomas associated with tuberous sclerosis complex in 11 children: presentation to outcome. *Pediatr Hematol Oncol* 2013;30(2):71–9.
  35. von Ranke FM, Zanetti G, e Silva JL, Araujo Neto CA, Godoy MC, Souza CA, et al. Tuberous sclerosis complex: state-of-the-art review with a focus on pulmonary involvement. *Lung* 2015;193(5):619–27.
  36. Hodgson N, Kinori M, Goldbaum MH, Robbins SL. Ophthalmic manifestations of tuberous sclerosis: a review. *Clin Exp Ophthalmol* 2017;45(1):81–6.
  37. Susana B, Barber I. Less common manifestations in TSC. *AJMG Part C: Seminars in Medical Genetics* 2018;178(3):348–54.
  38. Moulis H, Garsten JJ, Marano AR, Elser JM. Tuberous sclerosis complex: review of the gastrointestinal manifestations and report of an unusual case. *Am J Gastroenterol* 1992;87(7):914–8.
  39. O'Callaghan F, Osborne JP. Endocrine, gastrointestinal, hepatic, and lymphatic manifestations of tuberous sclerosis complex. In: *Tuberous Sclerosis Complex*. Kwiatkowski DJ, Whittermpre VH, Thiele EA, editors. Weinheim: Wiley-Blackwell, 2010.
  40. Tunali N, Gümürdülü D, Zorludemir S. Splenic involvement in a stillborn fetus with tuberous sclerosis



- and multiple cardiac rhabdomyomas. *Turk J Pediatr* 2004;46(4):357–61.
41. Morrison PJ. Tuberous sclerosis: epidemiology, genetics and progress towards treatment. *Neuroepidemiology* 2009;33(4):342–3.
  42. Wataya-Kaneda M, Tanaka M, Hamasaki T, Katayama I. Trends in the prevalence of tuberous sclerosis complex manifestations: an epidemiological study of 166 Japanese patients. *PLoS One* 2013;8(5):e63910.
  43. Manning BD, Cantley LC. United at last: the tuberous sclerosis complex gene products connect the phosphoinositide 3-kinase/Akt pathway to mammalian target of rapamycin (mTOR) signalling. *Biochem Soc Trans* 2003;31(Pt 3):573–8.
  44. Cappellano AM, Senerchia AA, Adolfo F, Paiva PM, Pinho R, Covic A, et al. Successful everolimus therapy for SEGA in pediatric patients with tuberous sclerosis complex. *Childs Nerv Syst* 2013;29(12):2301–5.
  45. Thiele EA. Managing epilepsy in tuberous sclerosis complex. *J Child Neurol* 2004;19(9):680–6.
  46. Canevini MP, Kotulska-Jozwiak K, Curatolo P, La Briola F, Peron A, Słowińska M, et al. Current concepts on epilepsy management in tuberous sclerosis complex. *Am J Med Genet C Semin Med Genet* 2018;178(3):299–308.
  47. de Vries PJ, Whittemore VH, Leclezio L, Byars AW, Dunn D, Ess KC, et al. Tuberous sclerosis associated neuropsychiatric disorders (TAND) and the TAND Checklist. *Pediatr Neurol* 2015;52(1):25–35.
  48. Leclezio L, Jansen A, Whittemore VH, de Vries PJ. Pilot validation of the tuberous sclerosis-associated neuropsychiatric disorders (TAND) checklist. *Pediatr Neurol* 2015;52(1):16–24.
  49. Takia L, Jat KR, Mandal A, Kabra SK. Lymphangioma (LAM) presenting as recurrent pneumothorax in an infant with tuberous sclerosis: treated successfully with sirolimus. *BMJ Case Rep* 2018;2018:bcr2018226244.
  50. Johnson SR, Cordier JF, Lazor R, Cottin V, Costabel U, Harari S, et al; Review Panel of the ERS LAM Task Force. European Respiratory Society guidelines for the diagnosis and management of lymphangioma. *Eur Respir J* 2010;35(1):14–26.
  51. Koenig MK, Bell CS, Hebert AA, Roberson J, Samuels JA, Slopis JM, et al; TREATMENT Trial Collaborators. Efficacy and safety of topical rapamycin in patients with facial angiofibromas secondary to tuberous sclerosis complex: The TREATMENT randomized clinical trial. *JAMA Dermatol* 2018;154(7):773–80.
  52. Bissler JJ, Kingswood JC, Radzikowska E, Zonnenberg BA, Belousova E, Frost MD, et al. Everolimus long-term use in patients with tuberous sclerosis complex: Four-year update of the EXIST-2 study. *PLoS One* 2017;12(8):e0180939.
  53. Yates DH. mTOR treatment in lymphangioma: the role of everolimus. *Expert Rev Respir Med* 2016;10(3):249–60.
  54. Hinton RB, Prakash A, Romp RL, Krueger DA, Kniffler TK; International Tuberous Sclerosis Consensus Group. Cardiovascular manifestations of tuberous sclerosis complex and summary of the revised diagnostic criteria and surveillance and management recommendations from the International Tuberous Sclerosis Consensus Group. *J Am Heart Assoc* 2014;3(6):e001493.
  55. Aw F, Goyer I, Raboisson MJ, Boutin C, Major P, Dahdah N. accelerated cardiac rhabdomyoma regression with everolimus in infants with tuberous sclerosis complex. *Pediatr Cardiol* 2017;38(2):394–400.
  56. Park H, Chang CS, Choi SJ, Oh SY, Roh CR. Sirolimus therapy for fetal cardiac rhabdomyoma in a pregnant woman with tuberous sclerosis. *Obstet Gynecol Sci* 2019;62(4):280–4.